


Electrical Impedance Tomography and Prone Position During Ventilation in COVID-19 Pneumonia: Case Reports and a Brief Literature Review

Seminars in Cardiothoracic and Vascular Anesthesia
1–6
© The Author(s) 2020
Article reuse guidelines:
sagepub.com/journals-permissions
DOI: 10.1177/1089253220958912
journals.sagepub.com/home/scv


Serena Tomasino, MD¹, Rosa Sassanelli, MD^{1,2},
Corrado Marescalco, MD^{1,2}, Francesco Meroi, MD^{1,2} ,
Luigi Vetrugno, MD^{1,2}, and Tiziana Bove, MD^{1,2}

Abstract

At the end of 2019, a novel coronavirus (COVID-19) was identified as the cause of a cluster of pneumonia cases, with high needs of mechanical ventilation in critically ill patients. It is still unclear whether different types of COVID-19 pneumonia require different ventilator strategies. With electrical impedance tomography (EIT) we evaluated, in real time and bedside, the distribution of ventilation in the different pulmonary regions before, during, and after pronation in COVID-19 respiratory failure. We present a brief literature review of EIT in non-COVID-19 patients and a report of 2 COVID-19 patients: one that did not respond well and another one that improved during and after pronation. EIT might be a useful tool to decide whether prone positioning should or should not be used in COVID-19 pneumonia.

Keywords

electrical impedance tomography, pneumonia, prone position, COVID-19, ventilation

Background

At the end of 2019, a novel coronavirus (COVID-19) was identified as the cause of a cluster of pneumonia cases in the Chinese city of Wuhan,¹ rapidly spreading worldwide resulting in a global pandemic.² The virus was designated severe acute respiratory syndrome coronavirus 2 (SARS-CoV-2).³

Pneumonia appears to be the most frequent serious manifestation of this infection, characterized by fever, cough, dyspnea, and bilateral infiltrates on chest imaging. Other features including upper respiratory tract symptoms, myalgia, diarrhea, and smell or taste disorders are also common. There are no specific clinical characteristics that can reliably distinguish COVID-19 from other viral respiratory infections.^{4,5}

Acute respiratory distress syndrome (ARDS) with profound acute hypoxemia can manifest shortly after the onset of dyspnea. The need for mechanical ventilation in those who are critically ill is high, ranging from 30% to 100%.^{6,7}

Even though COVID-19 pneumonia meets the ARDS Berlin definition, it can be considered a specific disease with peculiar characteristics.⁸ Whether different types of COVID-19 pneumonitis require different ventilator strategies is still unclear.⁹

Thoracic computed tomography (CT) scan is the gold standard for lung imaging for diagnosis and follow-up,

but it is expensive, carries radiation hazard, and requires transportation of critically ill infectious patients with all the associated risks. A second aspect to take into account is the epidemic peak of COVID-19. The medical chief of the Emergency Department of Bergamo (Italy) reported seeing up to 60 to 80 suspected COVID-19 patients in a few hours. That said, the execution of 30 CT scans per hour is unimaginable.¹⁰

Lung ultrasound is a bedside diagnostic tool for the evaluation of pulmonary and pleural pathology, but the specificity and sensitivity in COVID-19 patients has yet to be determined as well as a standardized protocol for its use.¹¹⁻¹³

In our clinical practice, we also use electrical impedance tomography (EIT; Pulmovista 500, Dräger) to evaluate, in real time and bedside, the distribution of ventilation in the different pulmonary regions in 2 patients with COVID-19 pneumonia.

¹University-Hospital of Udine, Udine, Italy

²University of Udine, Udine, Italy

Corresponding Author:

Francesco Meroi, Anesthesia and Intensive Care Clinic, Department of Medicine, University of Udine, Via Colugna n° 50, Udine 33100, Italy.
Email: francesco@hotmail.it

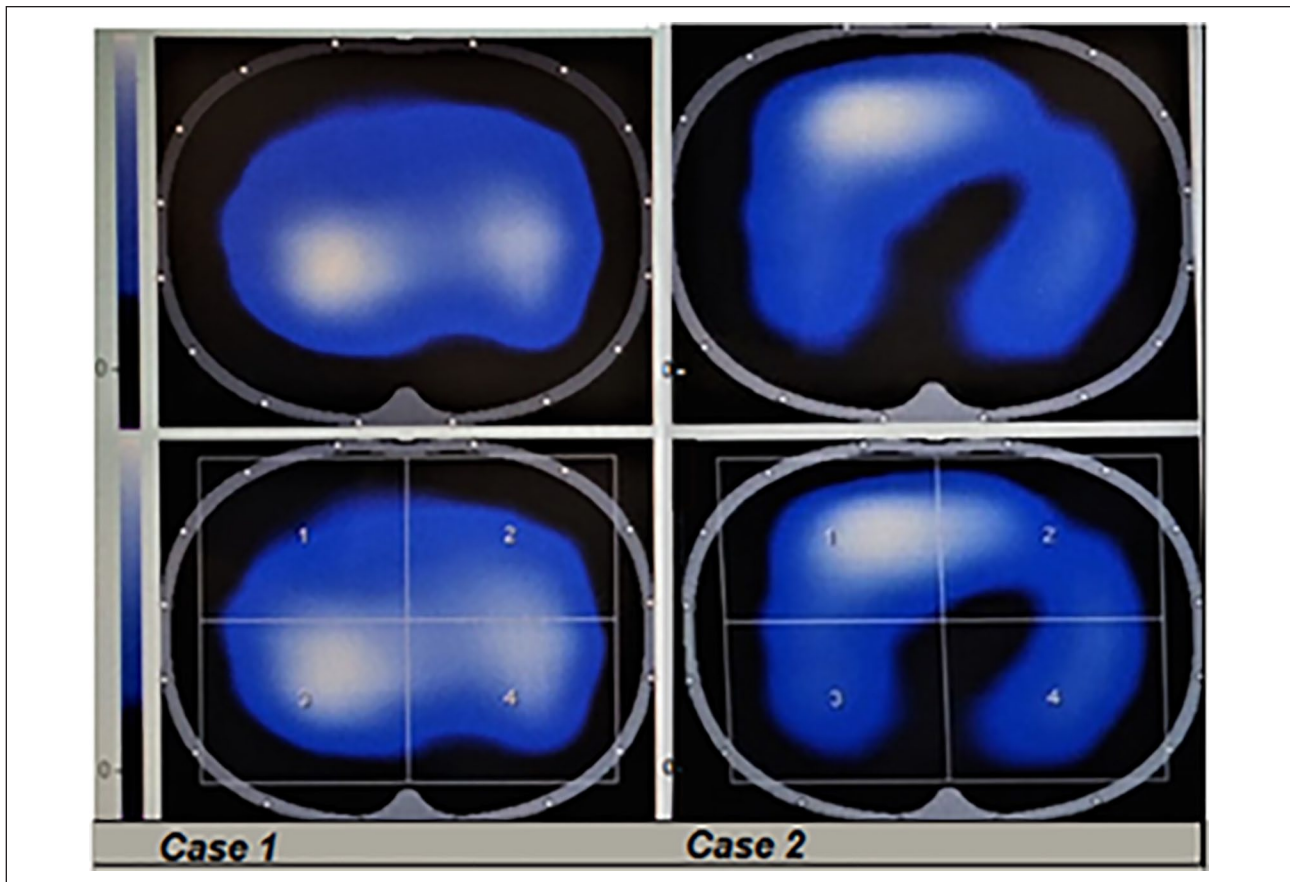


Figure 1. Electric impedance tomography of our 2 patients after a pronation cycle. The upper images represent T_0 and the lower T_3 . In the first case, region of interest (ROI) ratio was close to 1 at T_0 (homogeneity 25%) and decreased at T_3 (overdistension of the dorsal regions and de-recruitment of the ventral ones). In the second patient, the ventilation distribution seemed homogeneous between T_0 (ROI ratio = 1.2) and at T_3 (ROI ratio = 0.8).

Case Presentation

Case 1

A 68-year-old man with hypertension, diabetes, mild obesity, depression, and hypothyroidism was admitted to our University-Hospital with increasing dyspnea, with a 6-day history of fever and cough. A nasopharyngeal swab resulted positive for SARS-CoV-2 infection, and arterial gas analysis showed the following: pH of 7.27, PaO_2 (arterial partial pressure of oxygen) 72 mm Hg, PaCO_2 (arterial partial pressure of carbon dioxide) 70 mm Hg, and a $\text{PaO}_2/\text{FiO}_2$ (fraction of inspired oxygen; P/F) ratio of 200 mm Hg with a FiO_2 0.35. The chest X-ray had a typical COVID-19-related pattern and the thorax CT scan revealed multiple infiltrations in both lungs.

After 5 days of continuous positive airway pressure and medical therapy in the infectious disease ward, he developed severe respiratory failure and was admitted to the intensive care unit (ICU) for intubation and mechanical ventilation. After sedation and muscle relaxation, protective mechanical ventilation was started with tidal volume of 6

mL/ideal body weight, respiratory rate of 21 breaths/minute, best positive end-expiratory pressure (PEEP) of 10 cm H_2O , a driving pressure of 8 cm H_2O with a FiO_2 of 0.65, and a pulmonary compliance of 60 mL/cm H_2O .

Pulmovista 500 was applied before pronation. Region of interest (ROI) 1 and ROI 2 describe the right and the left ventral pulmonary regions, respectively, and ROI 3 and ROI 4 are the right and the left dorsal pulmonary regions, respectively. The total value of 4 ROI defining the best ventilation distribution and homogeneity is 100%, with each ROI accounting for 25%. ROI ratio is the ratio between the mean values of ventral (ROIs 1 and 2) and dorsal areas (ROIs 3 and 4) and represents a reliable measure of the ventilation distribution. These measures were recorded before pronation (T_0), 1 hour (T_1), and 16 hours (T_2) after pronation, and 1 hour after supination (T_3).

ROI ratio was close to 1 at T_0 , showing homogeneity of ventilation distribution, whereas at T_2 and T_3 (Figure 1) the ratio decreased because of overdistension of the dorsal regions associated with de-recruitment of the ventral ones, associated with a worsening compliance (53 mL/cm H_2O).

At T_0 the different regions showed values close to the homogeneity (25%). During the pronation cycle, a reduction in ROIs 1 and 2 values occurred, followed by an increase in ROIs 3 and 4. Oxygenation, compliance, and P/F ratio did not improve (Figure 2). After 11 days of mechanical ventilation, the patient was extubated, but he was intubated again the day after for acute dyspnea. He underwent tracheostomy because of the need for prolonged mechanical ventilation. Two days after tracheostomy, he was weaned from the ventilator and transferred to the sub-intensive care unit.

Case 2

A 65-year-old man, who developed fever and cough at home, presented to the emergency department 5 days later because of respiratory distress, with a first P/F ratio of 221 mm Hg and a positive nasopharyngeal swab for SARS-CoV-2 infection. The patient's medical history was characterized by chronic obstructive pulmonary disease with emphysema and an acquired hemophilia.

After 4 days of treatment in the infectious disease ward with noninvasive ventilation and other support therapies, he developed severe respiratory failure with a P/F ratio of 60 mm Hg. A thorax CT scan showed bilateral ground glass pattern associated with emphysema bubbles.

He was admitted to the ICU and started protective volume-controlled mechanical ventilation with tidal volume 6 mL/ideal body weight, best PEEP of 6 cm H_2O , driving pressure of 13 cm H_2O , a respiratory rate of 16 breaths/minute, a pulmonary compliance of 34 mL/cm H_2O with a FiO_2 0.75.

In supine position (T_0), the ventilation distribution registered using Pulmovista 500 was almost homogeneous (ROI ratio = 1.2), worsening at T_1 (ROI ratio = 2.1), with an overdistension of the ventral regions and a reduction in the dorsal ones. At T_2 , the ROI ratio improved (ROI ratio = 1.7) and at T_3 (ROI ratio = 0.8; Figure 1) was similar to T_0 . Oxygenation, P/F ratio, and pulmonary compliance augmented after pronation (Figure 2). After 14 days of mechanical ventilation, the patient developed a large pneumothorax that was drained. However, the overall clinical condition worsened, and the patient died.

Brief Literature Review About EIT

EIT is a noninvasive, radiation-free clinical imaging tool to monitor in real time and at bedside the distribution of pulmonary ventilation. It is a rather new technology that has been investigated in the medical field for more than 30 years, finding recently an interesting application in the study of the lung and its characteristics. There is still no consensus over the use of the EIT comparing it with other diagnostic and monitoring tools in the ICU setting, but

different studies analyzed its possible advantages in ARDS, but not yet proven in COVID-19 ARDS.¹⁴

EIT's temporal resolution is higher than CT or magnetic resonance imaging, since the sensor registers 25 to 50 cycles per second, corresponding to 25 to 50 images, allowing the evaluation of the lung under dynamic conditions. Nevertheless, CT has a much higher spatial resolution.¹⁵

With its high temporal resolution, EIT obtains regional measures of the lung tissue characterizing its heterogeneous behavior under dynamic conditions that could be used to guide mechanical ventilation.¹⁵ Experimental studies showed that EIT can be used to titrate PEEP and to evaluate the regional changes in lung parenchyma during and after recruitment maneuvers.¹⁶⁻¹⁸ Another experimental study underlined that tidal recruitment and end-expiratory overinflation can be assessed with EIT.¹⁹

In severe non-COVID-19 ARDS patients, it is used to optimize mechanical ventilation settings,²⁰ providing useful information when titrating personalized PEEP.²¹ Moreover, it might be helpful in evaluating the possibility of lung recruitment maneuvers, estimating recruitable alveolar collapse.²² EIT has been used to determine posture-dependent changes in ventilation in a clinical setting and to monitor the ventilation distribution after a change in position.²³ Experimental studies showed that the EIT might be useful in detecting early signs of pneumothorax or alveolar de-recruitment, increasing patient safety during mechanical ventilation.^{24,25}

On the other hand, there are some technical limitations. EIT obtains impedance images of an axial section of the thorax (5-10 cm), not analyzing the entire lung parenchyma with a low spatial resolution.¹⁷ EIT detects changes of the tissue but without absolute values, and preexisting conditions such as pleural effusion or consolidation cannot be identified. EIT cannot be used in patients with an implanted pacemaker or that present skin lesion in the areas where the EIT electrodes should be applied.

EIT may become a standard monitoring therapy in the near future for mechanical ventilation to optimally balance between ideal PEEP, avoid hyperinflation, and achieve optimal V/Q ratio. EIT data analysis may need large sequences of images and the role of artificial intelligence might be of crucial importance analyzing "big data." In the future, it will have a great potential role for personalized and precision medicine.¹⁵

Case Discussion

In a recent editorial, 2 phenotypes of COVID-19 interstitial pneumonia have been described: type 1 and type 2.⁹

Type 1 patients present severe hypoxemia associated with compliance >50 mL/cm H_2O . Hypoxemia is mainly caused by an increase in ventilation/perfusion mismatch. High PEEP and/or prone position does not improve

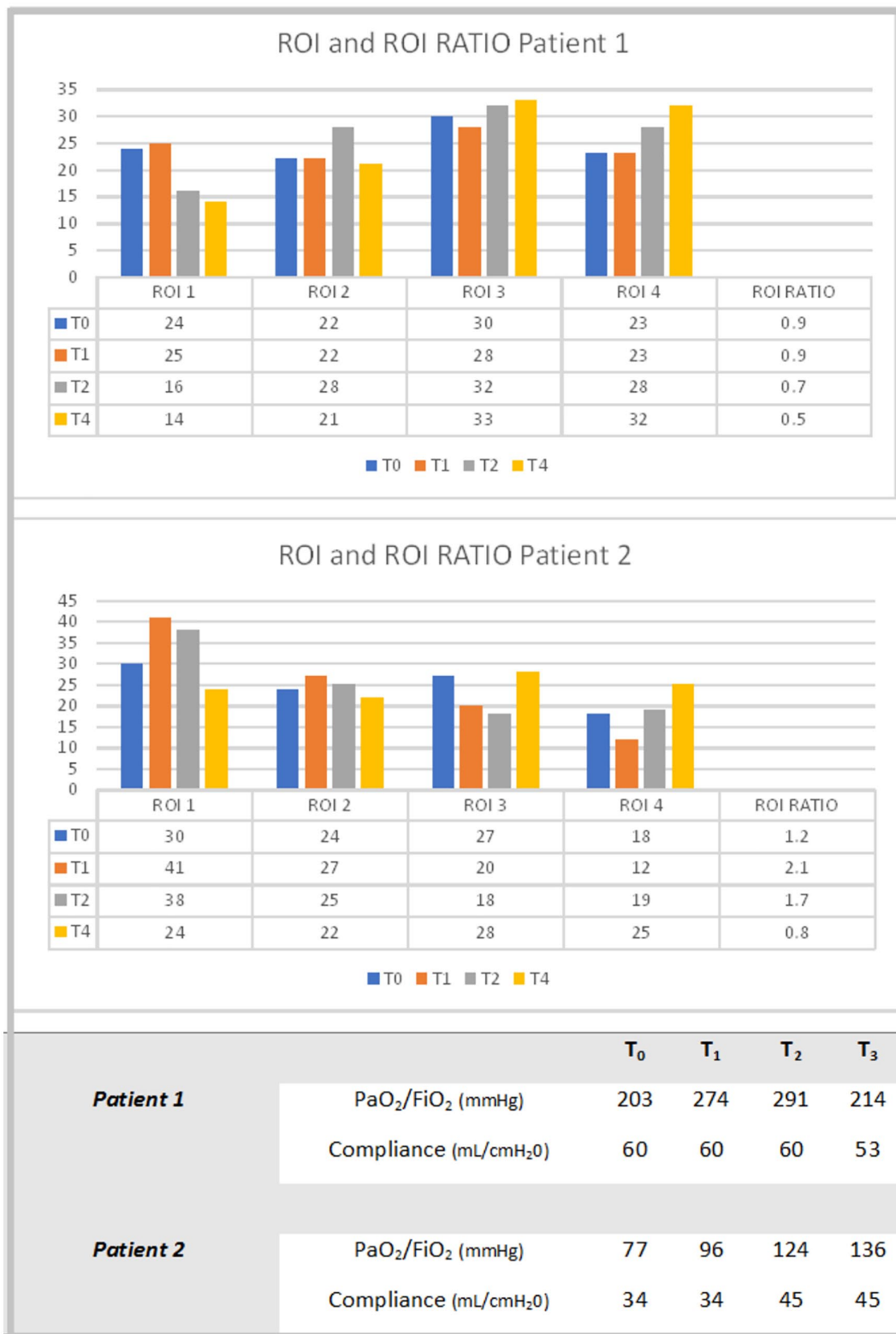


Figure 2. Comparison between ROI, ROI ratio, PaO₂/FiO₂ ratio, and compliance of our 2 patients. In the first patient ventilation distribution, oxygenation, P/F ratio, and compliance did not improve. The second patient presented a slight increase in ventilation of the dorsal areas comparing T₀ with T₃, as well as an increase in compliance and P/F ratio. Abbreviations: ROI, region of interest; T₀, before pronation; T₁, 1 hour after pronation; T₂, 16 hours after pronation; T₃, 1 hour after supination.

oxygenation because there are no areas to recruit, but might redistribute pulmonary perfusion, decreasing ventilation/perfusion mismatch.⁹

Type 2 patients have severe hypoxemia associated with compliance <40 mL/cm H₂O. The natural evolution of the disease might cause lower compliance but the severity of the damage might partially result from the initial ventilator management with noninvasive ventilation.

These patients present high respiratory drive, negative intrathoracic pressure, and inspiratory efforts that may cause a self-induced lung injury, especially in dorsal regions. In these patients, higher PEEP and prone positioning might be useful.⁹

In our first case, we saw with EIT a reduction in ventral ROI values, followed by an increase in dorsal ROI values during prone position. In this case, prone position might have not been indicated in this “high-compliance” pattern patient, since ventilation distribution, oxygenation, P/F ratio, and compliance did not improve.²⁶

The second case had conflicting EIT findings with regard to what we usually see in non-COVID-19 ARDS patients during the first pronation hours. However, comparing T₀ with T₃, we find a slight increase in dorsal areas ventilation, as expected according to Gattinoni’s type 2 patient description.

Conclusion

EIT is a safe, easy, cost-effective, and not operator-dependent bedside method to evaluate the ventilation distribution and pulmonary homogeneity. EIT potentially could be a useful tool to decide whether to use high PEEP or prone position: patients who have V/Q mismatch might be more responsive to position changes. EIT could be useful in identifying different COVID-19 pneumonia patterns and guiding ventilation strategies.

These characteristics might differentiate COVID-19 pneumonia patterns and could be a useful tool to decide whether prone position or high PEEP should or should not be used in COVID-19 pneumonia patients.

Declaration of Conflicting Interests

The author(s) declared no potential conflicts of interest with respect to the research, authorship, and/or publication of this article.

Funding

The author(s) received no financial support for the research, authorship, and/or publication of this article.

ORCID iD

Francesco Meroi  <https://orcid.org/0000-0002-7989-1605>

References

1. World Health Organization. Pneumonia of unknown cause—China. Published January 5, 2020. Accessed January 5, 2020. <https://www.who.int/csr/don/05-january-2020-pneumonia-of-unknown-cause-china/en/>
2. World Health Organization. Novel coronavirus—China. Published January 12, 2020. Accessed January 12, 2020. <https://www.who.int/csr/don/12-january-2020-novel-coronavirus-china/en/>
3. Lu R, Zhao X, Li J, et al. Genomic characterization and epidemiology of 2019 novel coronavirus: implications for virus origins and receptor binding. *Lancet*. 2020;395:565-574. doi:10.1016/S0140-6736(20)30251-8
4. Wang D, Hu B, Hu C, et al. Clinical characteristics of 138 hospitalized patients with 2019 novel coronavirus-infected pneumonia in Wuhan, China. *JAMA*. 2020;323:1061-1069. doi:10.1001/jama.2020.1585
5. Guan WJ, Ni ZY, Hu Y, et al. Clinical characteristics of coronavirus disease 2019 in China. *N Engl J Med*. 2020;382:1708-1720. doi:10.1056/NEJMoa2002032
6. Yang X, Yu Y, Xu J, et al. Clinical course and outcomes of critically ill patients with SARS-CoV-2 pneumonia in Wuhan, China: a single-centered, retrospective, observational study. *Lancet Respir Med*. 2020;8:475-481. doi:10.1016/S2213-2600(20)30079-5
7. Grasselli G, Zangrillo A, Zanella A, et al. Baseline characteristics and outcomes of 1591 patients infected with SARS-CoV-2 admitted to ICUs of the Lombardy Region, Italy. *JAMA*. 2020;323:1574-1581. doi:10.1001/jama.2020.5394
8. ARDS Definition Task Force; Ranieri VM, Rubenfeld GD, et al. Acute respiratory distress syndrome: the Berlin Definition. *JAMA*. 2012;307:2526-2533. doi:10.1001/jama.2012.5669
9. Gattinoni L, Chiumello D, Rossi S. COVID-19 pneumonia: ARDS or not? *Crit Care*. 2020;24:154. doi:10.1186/s13054-020-02880-z
10. Italian Society for Emergency Medicine (SIMEU). Accessed August 29, 2020. <https://www.simeu.it/w/articoli/leggiArticolo/3977/leggi>
11. Vetrugno L, Bove T, Orso D, et al. Our Italian experience using lung ultrasound for identification, grading and serial follow-up of severity of lung involvement for management of patients with COVID-19. *Echocardiography*. 2020;37:625-627. doi:10.1111/echo.14664
12. Guarracino F, Vetrugno L, Forfori F, et al. Lung, heart, vascular, and diaphragm ultrasound examination of COVID-19 patients: a comprehensive approach. *J Cardiothorac Vasc Anesth*. Published online June 11, 2020. doi:10.1053/j.jvca.2020.06.013
13. Denault AY, Delisle S, Canty D, et al. A proposed lung ultrasound and phenotypic algorithm for the care of COVID-19 patients with acute respiratory failure. *Can J Anaesth*. Published online May 21, 2020. doi:10.1007/s12630-020-01704-6
14. Frerichs I, Amato MB, van Kaam AH, et al. Chest electrical impedance tomography examination, data analysis, terminology, clinical use and recommendations: consensus statement of the TRanslational EIT developmeNt stuDY group. *Thorax*. 2017;72:83-93. doi:10.1136/thoraxjnl-2016-208357

15. Tomicic V, Cornejo R. Lung monitoring with electrical impedance tomography: technical considerations and clinical applications. *J Thorac Dis.* 2019;11:3122-3135. doi:10.21037/jtd.2019.06.27
16. Frerichs I, Dargaville PA, Dudykevych T, Rimensberger PC. Electrical impedance tomography: a method for monitoring regional lung aeration and tidal volume distribution? *Intensive Care Med.* 2003;29:2312-2316. doi:10.1007/s00134-003-2029-z
17. Odenstedt H, Lindgren S, Olegård C, et al. Slow moderate pressure recruitment maneuver minimizes negative circulatory and lung mechanic side effects: evaluation of recruitment maneuvers using electric impedance tomography. *Intensive Care Med.* 2005;31:1706-1714. doi:10.1007/s00134-005-2799-6
18. Meier T, Luepschen H, Karsten J, et al. Assessment of regional lung recruitment and derecruitment during a PEEP trial based on electrical impedance tomography. *Intensive Care Med.* 2008;34:543-550. doi:10.1007/s00134-007-0786-9
19. Zick G, Elke G, Becher T, et al. Effect of PEEP and tidal volume on ventilation distribution and end-expiratory lung volume: a prospective experimental animal and pilot clinical study. *PLoS One.* 2013;8:e72675. doi:10.1371/journal.pone.0072675
20. Bachmann MC, Morais C, Buggedo G, et al. Electrical impedance tomography in acute respiratory distress syndrome. *Crit Care.* 2018;22:263. doi:10.1186/s13054-018-2195-6
21. Spadaro S, Mauri T, Böhm SH, et al. Variation of poorly ventilated lung units (silent spaces) measured by electrical impedance tomography to dynamically assess recruitment. *Crit Care.* 2018;22:26. doi:10.1186/s13054-017-1931-7
22. Costa EL, Borges JB, Melo A, et al. Bedside estimation of recruitable alveolar collapse and hyperdistension by electrical impedance tomography. *Intensive Care Med.* 2009;35:1132-1137. doi:10.1007/s00134-009-1447-y
23. Spaeth J, Daume K, Goebel U, Wirth S, Schumann S. Increasing positive end-expiratory pressure (re-)improves intraoperative respiratory mechanics and lung ventilation after prone positioning. *Br J Anaesth.* 2016;116:838-846. doi:10.1093/bja/aew115
24. Bhatia R, Schmölder GM, Davis PG, Tingay DG. Electrical impedance tomography can rapidly detect small pneumothoraces in surfactant-depleted piglets. *Intensive Care Med.* 2012;38:308-315. doi:10.1007/s00134-011-2421-z
25. Costa EL, Chaves CN, Gomes S, et al. Real-time detection of pneumothorax using electrical impedance tomography. *Crit Care Med.* 2008;36:1230-1238. doi:10.1097/CCM.0b013e31816a0380
26. Dalla Corte F, Mauri T, Spinelli E, et al. Dynamic bedside assessment of the physiologic effects of prone position in acute respiratory distress syndrome patients by electrical impedance tomography. *Minerva Anesthesiol.* Published online May 22, 2020. doi:10.23736/S0375-9393.20.14130-0