

Regis Goulart Rosa¹, William Rutzen¹, Laura Madeira¹, Aline Maria Ascoli¹, Felipe Leopoldo Dexheimer Neto¹, Juçara Gasparetto Maccari¹, Roselaine Pinheiro de Oliveira¹, Cassiano Teixeira¹

1. Department of Intensive Care Medicine, Hospital Moinhos de Vento - Porto Alegre, Rio Gande do Sul (RS), Brazil.

Use of thoracic electrical impedance tomography as an auxiliary tool for alveolar recruitment maneuvers in acute respiratory distress syndrome: case report and brief literature review

Uso da tomografia por impedância elétrica torácica como ferramenta de auxílio às manobras de recrutamento alveolar na síndrome do desconforto respiratório agudo: relato de caso e breve revisão da literatura

ABSTRACT

Thoracic electrical impedance tomography is a real-time, noninvasive monitoring tool of the regional pulmonary ventilation distribution. Its bedside use in patients with acute respiratory distress syndrome has the potential to aid in alveolar recruitment maneuvers, which are often necessary in cases of refractory hypoxemia. In this case report, we describe the monitoring results and interpretation of thoracic electrical impedance tomography used during alveolar recruitment maneuvers

in a patient with acute respiratory distress syndrome, with transient application of high alveolar pressures and optimal positive end-expiratory pressure titration. Furthermore, we provide a brief literature review regarding the use of alveolar recruitment maneuvers and monitoring using thoracic electrical impedance tomography in patients with acute respiratory distress syndrome.

Keywords: Cardiography, impedance; Respiratory insufficiency/physiopathology; Monitoring, physiologic; Respiratory mechanics; Case reports

INTRODUCTION

Acute respiratory distress syndrome (ARDS) is characterized by acute onset respiratory failure associated with severe hypoxemia (oxygen partial pressure/fraction of inspired oxygen - $\text{PaO}_2/\text{FiO}_2 \leq 300\text{mmHg}$) and bilateral pulmonary infiltrates not fully explained by heart failure or fluid overload.⁽¹⁾ According to the Berlin criteria, ARDS may be classified as mild ($\text{PaO}_2/\text{FiO}_2$ ranging from 201 to 300mmHg), moderate ($\text{PaO}_2/\text{FiO}_2$ ranging from 101 to 200mmHg) or severe ($\text{PaO}_2/\text{FiO}_2 \leq 100\text{mmHg}$).⁽²⁾ ARDS continues to be correlated with high mortality rates, which may reach 36% to 44% in specialized centers, despite the progress made in treatment in recent decades.^(3,4)

Patients with ARDS often require intensive treatment using mechanical ventilation (MV), given the severity of their respiratory failure. However, MV may have deleterious effects on lung tissue and may even contribute to worsening of ARDS.⁽⁵⁻⁷⁾ This deleterious effect was demonstrated in studies evaluating the impact of MV with high tidal volumes and plateau pressure levels.^(8,9) Therefore, MV adjustment is recommended to avoid or minimize ventilator-associated lung injuries.⁽¹⁰⁻¹²⁾ This goal must be dynamically reached and should be based on information from the monitoring of the pulmonary function and respiratory mechanics of patients with ARDS.

Conflicts of interest: None.

Submitted on September 14, 2015
Accepted on November 22, 2015

Corresponding author:

Regis Goulart Rosa
Rua Ramiro Barcelos, 910/605
Zip code: 90035-001 - Porto Alegre (RS), Brazil
E-mail: regisgoulartrosa@gmail.com

Responsible editor: Carmen Valente Barbas

DOI: 10.5935/0103-507X.20150068

The use of alveolar recruitment maneuvers (ARM) has been proposed as complementary therapy to ventilation strategies for patients with severe ARDS and refractory hypoxemia.^(13,14) Those maneuvers aim to expand collapsed alveoli using a transient increase in transpulmonary pressure and by subsequently applying adequate positive end-expiratory pressure (PEEP) to prevent alveolar derecruitment. This strategy aims to strike an adequate balance between the number of collapsed and hyperextended alveoli, which reduces the pulmonary shunt and therefore improves the ventilation/perfusion ratio and hypoxemia.⁽¹⁵⁾

The bedside use of thoracic electrical impedance tomography (EIT) in patients with ARDS may be a key auxiliary tool for ARM by enabling clinicians to choose an optimal PEEP for maximum recruitment after considering key variables, including pulmonary static compliance (Cst), recruitable alveolar collapse and alveolar overdistension. That examination is based on existing differences in electrical properties generated by changes in air content in small lung areas, which create an impedance relationship between such areas.⁽¹⁶⁾ The pixels generated in the image of the monitor represent changes in the percentage of local impedance compared with a reference assessed in the beginning of the image acquisition. Thus, the dynamic image of the thoracic EIT monitor shows local air change during ventilation in real time. Color variation in the generated image shows areas within the alveoli that undergo air changes, with a scale ranging from dark blue (lower aeration) to light blue (higher aeration). Grey images represent areas in which no aeration change occurred.⁽¹⁶⁾ During the decremental PEEP titration maneuver, alveolar collapse may occur in specific lung areas (causing reduced Cst), and alveolar overdistension relief may occur in other lung areas (causing increased Cst). The degree of recruitable alveolar collapse is estimated by the reduction in pixel compliance, in relation to its best compliance, caused by the reduced PEEP value. Conversely, alveolar overdistension represents the reduction in pixel compliance, in relation to its best compliance, caused by increased PEEP.

In the present case report, we describe the application of thoracic EIT in a patient with severe ARDS during ARM with transient application of high alveolar pressures and optimal PEEP titration.

CASE REPORT

A 63-year-old Caucasian male patient with a diagnosis of liver cirrhosis caused by nonalcoholic steatohepatitis was admitted to the intensive care unit (ICU) of a tertiary hospital for severe community-acquired pneumonia. Upon hospital admission, the patient had fever, productive cough and dyspnea. Chest X-ray showed an initial focus of bronchopneumonic consolidation in the right lower lobe. The patient developed hypoxic respiratory failure associated with worsened pulmonary radiological condition, showing extensive bilateral alveolar consolidations, even after initiation of antibiotic therapy using piperacillin/tazobactam and clarithromycin, hydration and respiratory support with oxygen therapy by nasal cannula. Bedside transthoracic echocardiogram showed normal systolic function of the left and right ventricles. Following the diagnosis of ARDS, the patient was managed with continuous parenteral sedoanalgesia, neuromuscular block and protective MV with a tidal volume of 6 mL/kg predicted weight and PEEP/FIO₂ ratio according to the Acute Respiratory Distress Syndrome Network (ARDSnet) protocol.⁽⁹⁾ However, severe hypoxemia (112mmHg PaO₂/FiO₂) and high alveolar pressures (34cmH₂O plateau pressure) persisted, even after MV optimization. At that time, the patient was monitored using a Timpel Enlight 1800® (São Paulo, Brasil) thoracic electrical impedance tomograph (Figure 1), which showed asymmetric ventilation distribution (Figure 2), highlighting the hypoventilation of the left lung and posterior lung fields. Alveolar recruitment with transient application of high alveolar pressures, using the pressure-controlled ventilation mode (40cmH₂O PEEP, 20cmH₂O pressure above PEEP and 1:1 inspiratory/expiratory time ratio) for 2 minutes was used after normovolemia was confirmed using ultrasonographic evaluation of the inferior cava vein variability. No hemodynamic instability occurred during the process. The analysis of the thoracic EIT following ARM (Figure 3) showed improved lung ventilation distribution compared with the initial examination, highlighting the increased ventilation in previously collapsed areas. Following ARM, the optimal PEEP was calculated using the ratios between PEEP, Cst and alveolar collapse and overdistension indices (Figures 4, 5 and 6). Decremental PEEP titration was performed in 2-cmH₂O steps. The PEEP associated with

the highest Cst values and lowest alveolar collapse and overdistension values was chosen. Based on the analysis of the plot generated by the thoracic EIT, 16cmH₂O PEEP was deemed optimal in this situation because it showed the best ratio between Cst and alveolar collapse and overdistension; values lower than 16cmH₂O were associated with lower Cst values and higher lung collapse values, and PEEP values higher than 16cmH₂O were associated with higher values of alveolar overdistension. Then, the patient was recruited again, as described above, and the ventilatory parameters were maintained with a tidal volume of 6mL/kg predicted weight and 16cmH₂O PEEP. At this time, the plateau pressure measured was 26cmH₂O, and the PaO₂/FiO₂ ratio was 226mmHg.

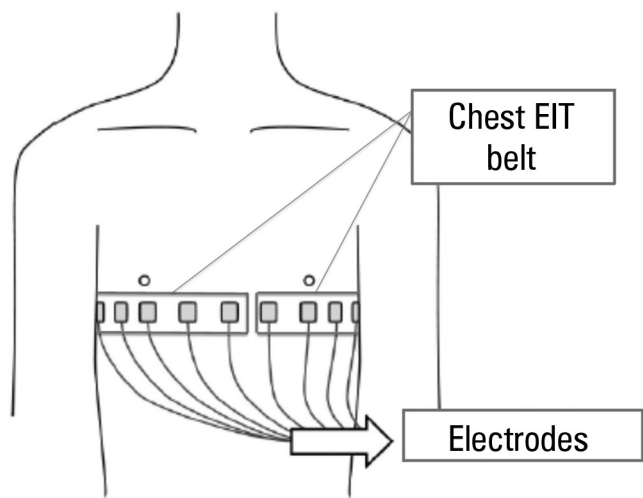


Figure 1 - Positioning of the electrodes for thoracic electrical impedance tomography. The electrodes for thoracic electrical impedance tomography are attached to the chest wall using a strap placed across the chest, near the level of the mammary line (between the fourth and fifth intercostal spaces). A flow sensor positioned between the endotracheal tube and the "Y" of the ventilator circuit is also connected to the monitor for electrical impedance tomography, in addition to the electrocardiogram electrodes (not shown in this Figure). EIT - electrical impedance tomography.

DISCUSSION

Alveolar recruitment may be defined as a strategy that transiently increases alveolar pressure above the regular tidal ventilation, including (but not limited to) sustained inflation maneuvers, gradual PEEP increase, tidal volume increase or controlled pressure and extended sighs. Alveolar recruitment aims to improve gas exchange through maximum recruitment of alveolar units, providing more homogeneous ventilation of the lung parenchyma. The ARM described in the case reported, with subsequent PEEP titration to maintain open lungs with an optimal

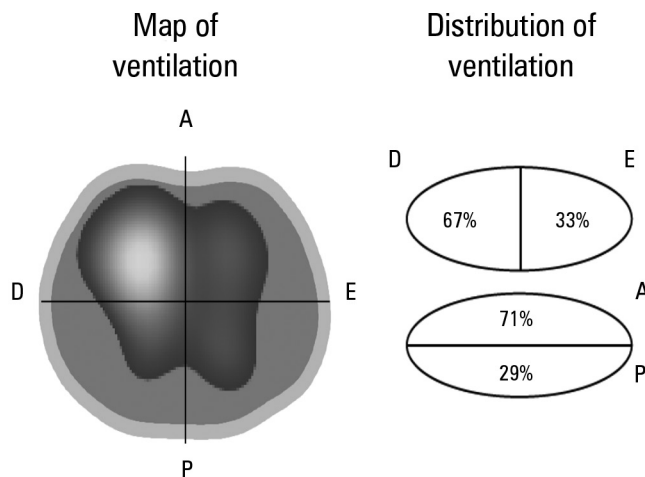


Figure 2 - Thoracic electrical impedance tomography: distribution of pulmonary ventilation before the alveolar recruitment maneuver. Image of a chest cross-section (at the level of the electrode position). An asymmetric distribution of alveolar ventilation is noted with reduced distribution of ventilation in the left lung and in posterior lung fields. R - right; L - left; A - anterior; P - posterior.

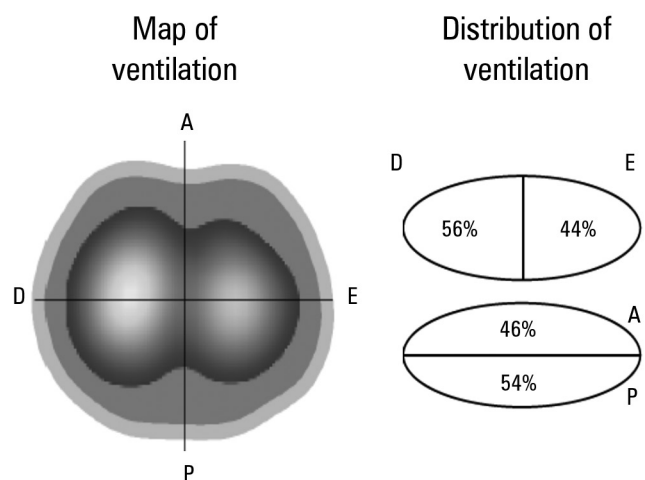


Figure 3 - Thoracic electrical impedance tomography: distribution of pulmonary ventilation after the alveolar recruitment maneuver. Image of a chest cross-section (at the level of the electrode position). A more homogeneous distribution of alveolar ventilation is noted in comparison with Figure 2. A higher ventilation of previously underventilated lung areas (left lung and posterior lung fields) occurred. R - right; L - left; A - anterior; P - posterior.

ratio between alveolar collapse and overdistension, was initially evaluated by computerized tomographic analysis.⁽¹⁷⁾ This strategy aims to open the lungs early and to keep them open, as initially advocated by Lachmann,⁽¹⁸⁾ in order to achieve improved lung function and avoid a potential lung injury associated with MV.⁽¹⁹⁾

Because ARDS is a biphasic disease that progresses from an acute exudative phase to an organization phase with persistent alveolar and interstitial fibrosis, early diagnosis, preferably within 72 hours, is crucial

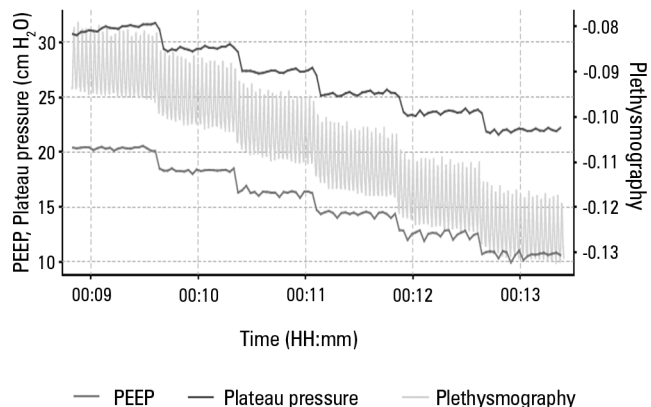


Figure 4 - Graphical representation of decremental positive end-expiratory pressure titration after the alveolar recruitment maneuver. Graphical representation of the plateau pressure performance and pulmonary plethysmography during the decremental positive end-expiratory pressure titration. PEEP - positive end-expiratory pressure.

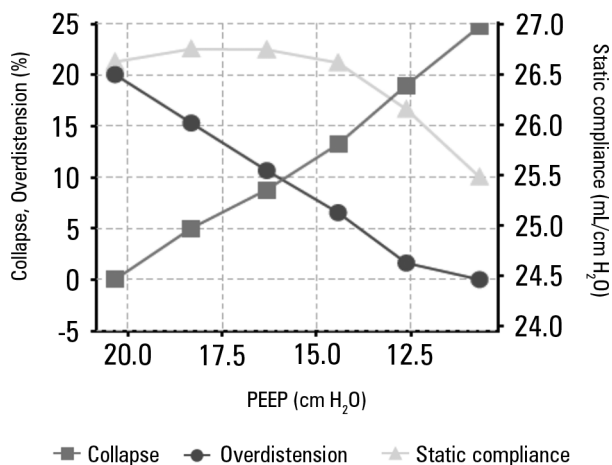


Figure 5 - Ratios between static compliance, alveolar collapse and alveolar overdistension according to the positive end-expiratory pressure applied. Graphical representation of the values of lung static compliance, alveolar collapse index and alveolar overdistension index for each positive end-expiratory pressure value. Note the decrease in alveolar overdistension index and increase in alveolar collapse index with the progressive decrease in positive end-expiratory pressure. The values of lung static compliance have a nonlinear correlation with the positive end-expiratory pressure, producing a more pronounced decrease in lung static compliance for positive end-expiratory pressure values lower than 15cmH₂O in this case. PEEP - positive end-expiratory pressure.

for effective ARM and for maintenance of alveolar opening with sufficient PEEP.⁽²⁰⁻²³⁾ A study analyzing 85 patients with ARDS classified according to the extent of fibroproliferation in the computed tomography scan showed that higher computed tomography scores were associated with a significant decrease in days free of organ dysfunction and days free of MV; higher scores were an independent risk factor for mortality (odds ratio: 1.2; 95% confidence interval [CI]: 1.06 - 1.36; p < 0.005).⁽²⁴⁾




Figure 6 - Thoracic electrical impedance tomography: alveolar collapse and overdistension areas according to the positive end-expiratory pressure applied. Graphical representation of the sites of occurrence of alveolar overdistension and collapse for each positive end-expiratory pressure applied. The hyperdistended areas are shown in white. The collapsed areas are shown in dark blue. The occurrence of alveolar overdistension is noted in anterior right lung fields for higher values of positive end-expiratory pressure. The occurrence of alveolar collapse is noted, especially in the left lung and posterior lung fields, for lower values of positive end-expiratory pressure. PEEP - positive end-expiratory pressure; R - right; L - left; A - anterior; P - posterior.

A recent meta-analysis⁽²⁵⁾ of 10 randomized clinical trials that evaluated the effects of ARM on patients with ARDS showed a risk ratio (RR) of 0.84 (95% CI: 0.74 - 0.95) for in-hospital mortality. However, the quality of evidence was low, given the risk of bias in the included studies, as ARM was usually performed in conjunction with other ventilatory interventions that may have affected the outcome of interest. In the present study, no differences were observed in the barotrauma rates (RR: 1.11; 95% CI: 0.78 - 1.57) or in the need for rescue therapies (RR: 0.76; 95% CI: 0.41 - 1.40). Most studies failed to show any difference between groups regarding the duration of MV and the length of ICU or hospital stay. Ongoing studies may best assess whether ARM should be routinely applied to optimize the clinical outcomes of patients with ARDS.^(26,27)

EIT is a noninvasive method of bedside monitoring that provides real-time information on the regional distribution of changes in the electrical resistivity of the lung tissue resulting from ventilation or blood flow (perfusion) variations in relation to a predetermined reference.^(28,29) Data provided by EIT may directly quantify local pulmonary impedance changes. Therefore, functionally active pulmonary structures are shown, while functionally static, normal or pathologically structures (for example, pleural or pneumothorax effusion) are not captured by the method and are not imaged. Several animal

and human studies have validated the pulmonary findings of thoracic EIT.^(30,31) However, that linear correlation fundamentally depends on the position of the electrode, changes in the thoracic wall and diaphragm shape and the ratio of tidal ventilation distributed in lung areas.⁽³²⁾

The definition of collapsed and overdistended lung areas may enable thoracic EIT to be used as a bedside clinical tool for adjusting the MV parameters. When calculating the potentially recruitable lung volume as the difference between the open, totally recruited and non-recruited lung volume at 40cmH₂O, Lowhagen et al.⁽³³⁾ observed a significant value of potentially recruitable lung volume of 26 ± 11% (11% to 47%) in patients with ARDS. The same group also analyzed the regional distribution of intratidal gas upon changes in regional lung mechanics using EIT data and airway pressure at different PEEP levels.⁽³⁴⁾ The tidal volume was primarily distributed in the medio-ventral areas, although the increase in PEEP caused redistribution into the more dorsal areas, regardless of the PEEP level. A recent clinical study showed that thoracic EIT performed immediately above the diaphragm could detect alveolar derecruitment during a decremental PEEP maneuver, both in dependent and non-dependent lung areas, and

also show alveolar collapse.⁽³⁵⁾ Recently, Costa et al.⁽³⁶⁾ evaluated a new algorithm to estimate hyperinsufflation during a decremental PEEP maneuver and showed that the hyperinsufflation lung areas were particularly similar when comparing EIT with CT, although EIT systematically had a higher overdistension coefficient. The authors concluded that the EIT estimates of hyperinsufflation mostly account for the functional deterioration of pulmonary units, rather than anatomic changes of those areas.

CONCLUSION

The bedside use of thoracic electrical impedance tomography may be a clinical tool that is able to guide, at each breath, possible adjustments of regional ventilation, including the decision for alveolar recruitment maneuvers, in patients with acute respiratory distress syndrome. Furthermore, electrical impedance tomography may refine the choice of optimal post-recruitment positive end-expiratory pressure, considering the quantification of possibly deleterious variables, including alveolar collapse and overdistension. Future studies are necessary to evaluate the use of this device combined with software to help identify situations in which mechanical ventilation could be optimized.

RESUMO

A tomografia por impedância elétrica torácica constitui ferramenta de monitorização não invasiva, em tempo real, da distribuição regional da ventilação pulmonar. Sua utilização à beira do leito em pacientes com síndrome do desconforto respiratório agudo tem o potencial de auxiliar na condução de manobras de recrutamento alveolar, frequentemente necessárias em casos de hipoxemia refratária. Neste relato de caso, apresentamos os resultados e a interpretação da monitorização da tomografia por impedância elétrica torácica em um paciente com síndrome do desconforto respiratório agudo, durante

manobras de recrutamento alveolar, com aplicação transitória de altas pressões alveolares e titulação da pressão positiva ao final da expiração ideal. Adicionalmente, apresentamos uma breve revisão da literatura a respeito do uso de manobras de recrutamento alveolar e monitorização com tomografia por impedância elétrica torácica em pacientes com síndrome do desconforto respiratório agudo.

Descritores: Cardiografia de impedância; Insuficiência respiratória/fisiopatologia; Recrutamento alveolar; Mecânica respiratória; Relatos de casos

REFERENCES

1. Silversides JA, Ferguson ND. Clinical review: Acute respiratory distress syndrome - clinical ventilator management and adjunct therapy. *Crit Care*. 2013;17(2):225. Review.
2. ARDS Definition Task Force, Ranieri VM, Rubenfeld GD, Thompson BT, Ferguson ND, Caldwell E, Fan E, et al. Acute respiratory distress syndrome: The Berlin definition. *JAMA*. 2012;307(23):2526-33.
3. Phua J, Badia JR, Adhikari NK, Friedrich JO, Fowler RA, Singh JM, et al. Has mortality from acute respiratory distress syndrome decrease over time? A systematic review. *Am J Resp Crit Care Med*. 2009;179(3):220-7. Review.
4. Zamboni M, Vincent JL. Mortality rates for patients with acute lung injury/ARDS have decreased over time. *Chest*. 2008;133(5):1120-7.
5. Matthay MA, Ware LB, Zimmerman GA. The acute respiratory distress syndrome. *J Clin Invest*. 2012;122(8):2731-40. Review.

6. Mazullo Filho JB, Bona S, Rosa DP, Silva FG, Forgiarini Junior LA, Dias AS, et al. The effects of mechanical ventilation on oxidative stress. *Rev Bras Ter Intensiva*. 2012;24(1):23-9.
7. Bugeo G, Bruhn A, Regueira T, Romero C, Retamal J, Hernández G. Positive end-expiratory pressure increases strain in patients with ALI/ARDS. *Rev Bras Ter Intensiva*. 2012;24(1):43-51.
8. Amato MB, Barbas CS, Medeiros DM, Magaldi RB, Schettino GP, Lorenzi-Filho G, et al. Effect of a protective-ventilation strategy on mortality in the acute respiratory distress syndrome. *N Engl J Med*. 1998;338(6):347-54.
9. Ventilation with lower tidal volumes as compared with traditional tidal volumes for acute lung injury and the acute respiratory distress syndrome. The Acute Respiratory Distress Syndrome Network. *N Engl J Med*. 2000;342(18):1301-8.
10. Girard TD, Bernard GR. Mechanical ventilation in ARDS: a state-of-the-art review. *Chest*. 2007;131(3):921-9. Review.
11. Barbas CS, Isola AM, Farias AM, Cavalcanti AB, Gama AM, Duarte AC, et al. Brazilian recommendations of mechanical ventilation 2013. Part 1. *Rev Bras Ter Intensiva*. 2014;26(2):89-121.
12. Barbas CS, Isola AM, Farias AM, Cavalcanti AB, Gama AM, Duarte AC, et al. Brazilian recommendations of mechanical ventilation 2013. Part 2. *Rev Bras Ter Intensiva*. 2014;26(3):215-39.
13. Keenan JC, Formenti P, Marini JJ. Lung recruitment in acute respiratory distress syndrome: what is the best strategy? *Curr Opin Crit Care*. 2014;20(1):63-8.
14. Chiumello D, Froio S, Bouhemad B, Camporota L, Coppola S. Clinical review: Lung imaging in acute respiratory distress syndrome patients - an update. *Crit Care*. 2013;17(6):243. Review.
15. Marini JJ. Recruitment maneuvers to achieve an "open lung" -- whether and how? *Crit Care Med*. 2001;29(8):1647-8.
16. Frerichs I, Dargaville PA, Dudykevych T, Rimensberger PC. Electrical impedance tomography: a method for monitoring regional lung aeration and tidal volume distribution? *Intensive Care Med*. 2003;29(12):2312-6.
17. Borges JB, Okamoto VN, Matos GF, Caramez MP, Arantes PR, Barros F, et al. Reversibility of lung collapse and hypoxemia in early acute respiratory distress syndrome. *Am J Respir Crit Care Med*. 2006;174(3):268-78.
18. Lachmann CB. Open up the lung and keep the lung open. *Intensive Care Med*. 1992;18(6):319-21.
19. Barbas CS, de Matos GF, Pincelli MP, da Rosa Borges E, Antunes T, de Barros JM, et al. Mechanical ventilation in acute respiratory failure: recruitment and high positive end-expiratory pressure are necessary. *Curr Opin Crit Care*. 2005;11(1):18-28. Review.
20. Su L, Zhai R, Sheu CC, Gallagher DC, Gong MN, Tejera P, et al. Genetic variants in the angiotensin-converting enzyme 2 gene are associated with increased risk of ARDS. *Intensive Care Med*. 2009;35(6):1024-30.
21. Karcz M, Vitkus A, Papadakos PJ, Schwaiberger D, Lachmann B. State-of-the-art: mechanical ventilation. *J Cardiothorac Vasc Anesth*. 2012;26(3):486-506.
22. Barbas CS. Understanding and avoiding ventilator-induced lung injury: lessons from an insightful experimental study. *Crit Care Med*. 2010;38(12):2418-9.
23. Barbas CS, de Matos GF. Best strategy to recruit primary ARDS: what to look for. *Minerva Anesthesiol*. 2010;76(9):681-3.
24. Ichikado K, Muranaka H, Gushima Y, Kotani T, Nader HM, Fujimoto K, et al. Fibroproliferative changes on high-resolution CT in the acute respiratory distress syndrome predict mortality and ventilator dependency: a prospective observational cohort study. *BMJ Open*. 2012;2(2): e000545.
25. Suzumura EA, Figueiró M, Normilio-Silva K, Laranjeira L, Oliveira C, Buehler AM, et al. Effects of alveolar recruitment maneuvers on clinical outcomes in patients with acute respiratory distress syndrome: a systematic review and meta-analysis. *Intensive Care Med*. 2014;40(9):1227-40.
26. ART Investigators. Rationale, study design, and analysis plan of the Alveolar Recruitment for ARDS Trial (ART): study protocol for a randomized controlled trial. *Trials*. 2012;13:153.
27. Hodgson C, Nichol A. A multi-centre trial of an open lung strategy including permissive hypercapnia, alveolar recruitment and low airway pressure in patients with acute respiratory distress syndrome (PHARLAP). 2012; ClinicalTrials.gov registration number: NCT00431158.
28. Bodenstein M, David M, Markstaller K. Principles of electrical impedance tomography and its clinical application. *Crit Care Med*. 2009;37(2):713-24. Review.
29. Bayford RH. Bioimpedance tomography (electrical impedance tomography). *Annu Rev Biomed Eng*. 2006;8:63-91. Review.
30. Muders T, Luepschen H, Putensen C. Impedance tomography as a new monitoring technique. *Curr Opin Crit Care*. 2010;16(3):269-75.
31. Lu Q. How to assess positive end-expiratory pressure-induced alveolar recruitment? *Minerva Anesthesiol*. 2013;79(1):83-91. Review.
32. Lundin S, Stenqvist O. Electrical impedance tomography: potentials and pitfalls. *Curr Opin Crit Care*. 2012;18(1):35-41.
33. Lowhagen K, Lindgren S, Odenstedt H, Stenqvist O, Lundin S. A new non-radiological method to assess potential lung recruitability: a pilot study in ALI patients. *Acta Anaesthesiol Scand*. 2011;55(2):165-74.
34. Lowhagen K, Lundin S, Stenqvist O. Regional intratidal gas distribution in acute lung injury and acute respiratory distress syndrome -- assessed by electric impedance tomography. *Minerva Anesthesiol*. 2010;76(12):1024-35.
35. Bikker IG, Leonhardt S, Reis Miranda D, Bakker J, Gommers D. Bedside measurement of changes in lung impedance to monitor alveolar ventilation in dependent and nondependent parts by electrical impedance tomography during a positive end-expiratory pressure trial in mechanically ventilated intensive care unit patients. *Crit Care*. 2010;14(3):R100.
36. Costa EL, Borges JB, Melo A, Suarez-Sipmann F, Toufen C Jr, Bohm SH, et al. Bedside estimation of recruitable alveolar collapse and hyperdistension by electrical impedance tomography. *Intensive Care Med*. 2009;35(6):1132-7.