

Neurological pupil index for coma prognostication in critically ill patients with non-anoxic brain injury



F. Romagnosi ^{1,2}, A. Bernini ^{1,2}, F. Bongiovanni^{1,4}, C. Iaquaniello ^{1,3}, JP. Miroz¹, G. Citerio³, FS Taccone⁵, M. Oddo^{1,6}

¹ Neuroscience Critical Care group, Department of Intensive Care Medicine, Centre Hospitalier Universitaire Vaudois (CHUV), Switzerland; ² Unit of Anesthesia and Intensive Care A, Department of Anesthesia and Intensive Care Medicine, University Hospital Integrated Trust of Verona, Verona, Italy; ³ School of Medicine and Surgery, University of Milano - Bicocca, Monza, Italy; ⁴ Department of Anesthesiology and Intensive Care Medicine, Catholic University of The Sacred Heart, Roma, Italy; ⁵ Department of Intensive Care Medicine, Erasme Hospital, Université Libre de Bruxelles, Brussels, Belgium; ⁶ Medical Direction for Research, Education and Innovation, CHUV, Lausanne, Switzerland.

OBJECTIVES

➤ The prognostic value of quantitative pupillometry, with the use of the Neurological pupil index (NPi) in patients with primary non-anoxic brain injury.

METHODS

- **Retrospective** cohort study (October 2016-March 2019) of critically ill patients with non-anoxic brain injury underwent concomitant monitoring of NPi and intracranial pressure (ICP).
- For each patient, **abnormal NPi** and high ICP were quantified by calculating the percentage of measurements with NPi <3 and ICP >20 mmHg.
- **Six months neurological outcome** was dichotomized as favourable (GOS 4-5) vs. unfavourable (GOS 1-3).
- **Three NPi pattern** were identified (Figure 1)

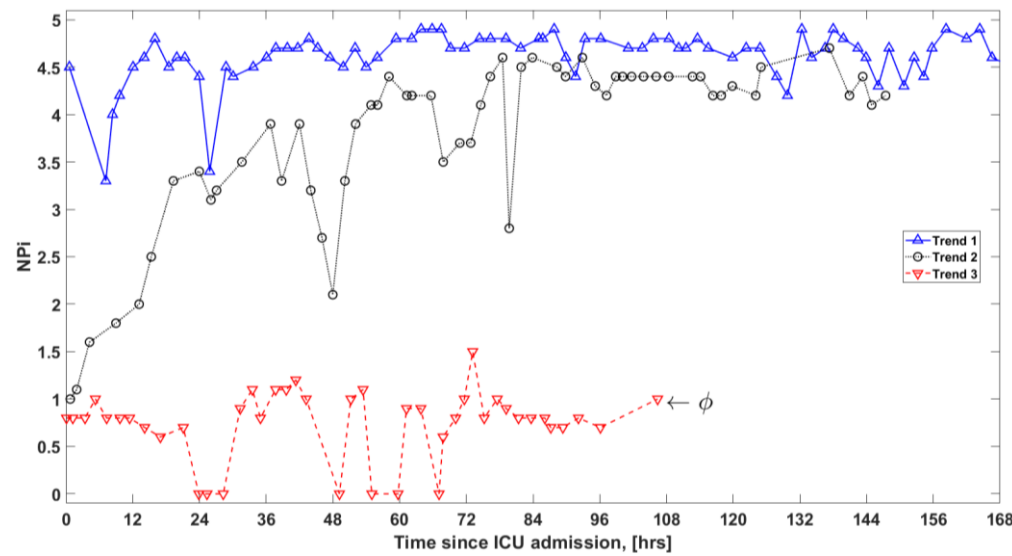


Figure 1. Early NPi patterns.

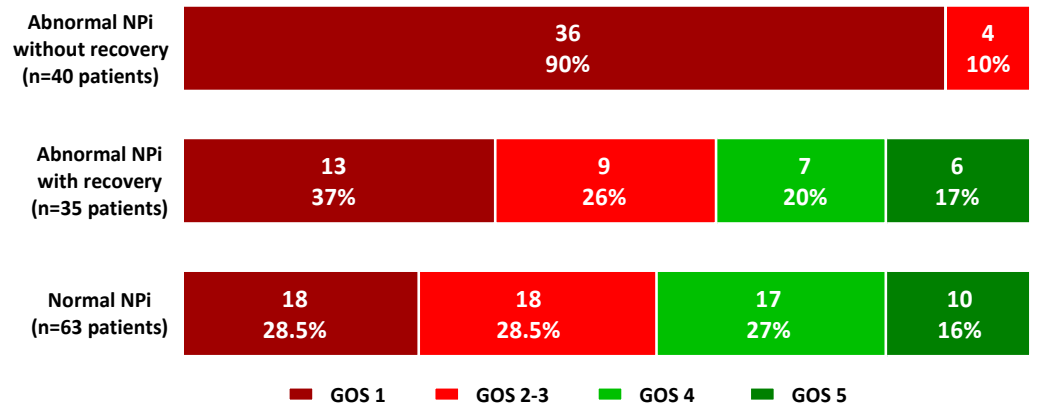


Figure 2. Outcome at six months as a function of individual NPi patterns.

RESULTS

- **138 patients** with **severe brain injury** (63 traumatic, 75 non-traumatic), of which 91% had high ICP and 67% had CT signs of brain herniation.
- Subjects with unfavourable outcome were more likely to have abnormal NPi (3% [95% confidence interval 0-5%] vs. 24% [17-30%], $p < 0.001$) and high ICP (4% [1-7%] vs. 18% [12-24%], $p = 0.048$).
- In a multivariate model, after adjusting for age, brain CT signs and high ICP, **abnormal NPi was associated with unfavourable six-month outcome** (odds ratio [OR] 1.15 [1.03-1.28], $p = 0.013$).
- Among patients with a **persistently abnormal NPi pattern**, none had favourable 6 month neurological outcome (0/40). (Figure 2)

CONCLUSIONS

- Pathologic NPi was associated with unfavourable neurological outcome, independently from age, brain injury severity and elevated ICP.
- Integration of individual NPi patterns would provide critical information on long-term patient prognosis.